

# Duration Exposure effect of Anti Mosquito Coils smoke on Lung and Microscopic condition of Heart and Haemoglobin in Mice

*by RA*

---

**Submission date:** 07-Jun-2023 11:31PM (UTC-0400)

**Submission ID:** 2111479312

**File name:** ration\_Exposure\_effect\_of\_Anti\_Mosquito\_Coils\_smoke\_on\_Lung.pdf (352.55K)

**Word count:** 3973

**Character count:** 19880

RESEARCH ARTICLE

## Duration Exposure effect of Anti Mosquito Coils smoke on Lung and Microscopic condition of Heart and Haemoglobin in Mice (*Mus musculus*)

Aivrida Mega Charisma\*, Fifin Aristian, Refilda Ningtyas, Farida Anwari

DIII Teknologi Laboratorium Medis, STIKES RS Anwar Medika, Sidoarjo, Indonesia

\*Corresponding Author E-mail: acie.vrida@gmail.com

### ABSTRACT:

The use of mosquito coils for a long time will harm the body, including the lungs and heart. Therefore, this study aims determine the microscopic condition of the lungs and heart and hemoglobin levels. The design of this study was a laboratory experiment that used sample of 24 mice divided into 4 groups, named P0(control), P1(4 hours), P2(6 hours), and P3(8 hours) for 30 days. Then the hemoglobin level was measured using the POCT method. After that, the mice were necropsied the observe the condition of the lungs and heart which had been stained with HE. Observations were conducted inscoring and process data using statistical test of one way ANOVA, if the data are not qualified, then Kruskal-walis test is used The results showed that the degree of lung damage obtained a score of P0, P1, P2, and P3 of 1.5;2;2,167; and 2,667. While the degree of hearth damage P0, P1, P2, and P3 obtained score of 0.5;1.5;1.3; and 1.67. The results of hemogobin levels (g/dl) showed that P0, P1, P2, P3 of 14.61; 17.4; 15.05; and 17.4. Microscopically, lung cell tissue was damaged when exposed to mosquito coil smoke, it is the presence of pycenotic nuclei in P2 and P3 treatments. The results of One Way ANOVA test on hemoglobin levels of mice showed significant results ( $p>0.05$ ), while microscopically, heart cells using the Kruskal Wallis test showed significant differences ( $p>0.05$ ). The conclusion of this study is that there is a significant chane between the leghth of time of exposure to mosquito coils with lung microscopy and the level of mice. However, there were no significant changes in the microscopic heart of mice.

**KEYWORDS:** Mosquito coils, heart, lungs, hemoglobin.

### INTRODUCTION:

Indonesia has geographical conditions that support the proliferation of various types of mosquitoes which are vectors of dengue, malaria, chikungunya fever, and filariasis. Thus, the community will be likely affected and experience death.<sup>1</sup> Therefore, the government recommends the use of mosquito repellent which is now widely circulated in the market. One of them is mosquito coils. This type of mosquito repellent is widely used by the public for a reasonably price, easy to obtain sad easy to use.<sup>2</sup>

However,<sup>3</sup> according to the smoke produced from mosquito coils contains free radicals which have molecules of one or more unpaired electrons so that the compounds become very reactive to body cells by binding to the electrons of cell molecules that are attached to the body which will eventually lead to oxidation.

This is dangerous for the body because the levels of oxidants in hemoglobin become high, and as the result, the body cells such as lungs and heart will lack of oxygen, especially for continuous, long-term usage. The disruption of the blood toward tissues throughout the body will result in health problems and death. Therefore, this study was conducted to observe the histopathological changes of the heart and lungs as well as hemoglobin in the allotted time.

### MATERIAL AND METHODS:

#### Material Selection:

Male mice, husks, pellet feed, mosquito repellent, aquades, 10% formalin from the Integrated Biology

Laboratory of Stikes Hospital Amerta Medika. Haemotoxylin eosin (HE) dye, paraffin, 70% alcohol, 80% alcohol, 90% alcohol, 100% alcohol, xylol, absolute alcohol from the Laboratory of Anatomical Pathology, Faculty of Medicine, Airlangga University, Surabaya. Whereas tools needed in this study included a plastic mouse cage, a special plastic box with one ventilation hole, a place to eat and drink for mice, wire bars, analytical scales, beaker glass, sample pot, measuring cup, spatula, sectioning set, tools easy touch, hemoglobin strip, ruler, surgical board, pin from the Integrated Biology laboratory of STIKES RS Anwar Medika. Tissue cassette, base mould, oven, water bath, staining jar, processing jar, microtome from the Anatomical Pathology Laboratory, Faculty of Medicine, Airlangga University, Surabaya.

#### Experimental Animal Preparation:

Mark the mice according to the treatment to avoid errors in the treatment then put them in a plastic box with 6 heads of husks, mark P0, P1, P2, and P3 on 4 plastic tubs that already contain 6 mice, and feeding and then drinking ad libitum

#### Stages of Implementation of Treatment:

The mice fasted for 24 hours to be treated according to the label on the plastic tub, after that Mice were exposed to smoke of mosquito coils for 4 hours, 8 hours, and 12 hours for 30 days, and then stabbing blood samples on the tails of mice using autoclick on the 31st day which then measured the hemoglobin level on the device easy touch (POCT method), Performing a necropsy or surgery on mice by dislocating the neck and then taking the lungs and heart organs, make macroscopic observations on color, measure diameter, and weigh the lungs and heart organs, wash the lungs and heart with NaCl. Then put it in a container containing 10% formalin as a fixation and then labeled according to the treatment category for at least 24 hours, process the tissue to the dehydration stage by immersing it in 85% graded alcohol (1x) 2 hours, 95% (2x) 2 hours and 1 hour and absolute alcohol (3x) 1 hour, next step is clearing by soaking xylol (3x) 1 hour, the next step is embedding by immersing it into liquid paraffin at a temperature of 60°C (3x) 2 hours, next step is blocking by pouring liquid paraffin in the base mold then insert the heart organ and pour the paraffin back onto the tissue cassette and let it solidify then put it in the refrigerator. The next step is cutting by opening the paraffin mold and placing it on an ice cube and attaching the block to the microtome. Attach a knife and set a thickness of 5m for animal organs and cut until you get the desired sample portion and take the cut slices using tweezers or a brush, put the slices in a water bath at a temperature of 40-45°C to expand the slices then catch the pieces of tissue with aobject glass and place them on

a hotplate at a temperature of 60-62°C until the paraffin melts, next step is staining xylol (3x) for 5 minutes, absolute alcohol (2x) for 3 minutes, alcohol 90%, 80% for 3 minutes, distilled water for 2 minutes, HE for 5 minutes, running water for 3 minutes, eosin 1% for 2 minutes, alcohol 70%, 80%, 90% 3 minutes, absolute alcohol (2x) 5 minutes, xylol (2x) 5 minutes, finally perform the macroscopic histopathological observations at 400x magnification and count the cells undergoing necrosis

#### Experimental design:

The study was conducted using an *experimental laboratory method* with a *post test only control group design* approach because it was set to determine the effect of the duration of exposure to mosquito coils on histopathological conditions of the heart, lungs, and hemoglobin as well. The samples used were 24 mice. Each sample was divided into 4 groups, named P0 (untreated), P1(for 4 hours), P2(for 6 hours), and P3(for 8 hours). The procedure of this research consisted of 2stages, including preparation of experimental animals and implementation of treatment. In the preparation of experimental animals, mice were grouped and given appropriate treatment for 30 days. While in the implementation of the treatment, blood was taken to see the hemoglobin level using the POCT method. After that, surgery is conducted to take the heart and lungs which will be observed for histopathological changes using the *scoring* method with the criteria in table 1.

Table 1: Criteria for the degree of histopathological damage to the heart and lungs (Dharmawan, 2010)

S. No.	Damage Rate in Mice Heart Histopathology	Score
1.	Normal	0
2.	Mild damage, ie if there is a pycnotic nucleus between normal cells or pycnotic cells <25% of the entire visual field.	1
3.	Moderate damage, ie if the pycnotic core is 25-50% of the entire field of view.	2
4.	Severe damage, ie if the pyknotic nucleus >50% of the entire field of view and other more severe damage.	3

#### Research data collection:

Mice adapted for 7 days were fasted for 24 hours first. Then they were given exposure to the smoke of mosquito coils for 4 hours, 8 hours, and 12 hours for 30 days. On the 31st day, blood sampling was carried out in the tails of mice to measure hemoglobin levels using the POCT method. Then the mice were necropsied by neck dislocation and the lungs and heart were taken. Furthermore, the lungs and heart were observed macroscopically (color, diameter, and weight) and the organs were made histopathological preparations for microscopic observation (number of necrotic cells).

**Data analysis:**

The results of the data obtained consisted of several parts, namely the measurement of hemoglobin (hb) levels in the blood of mice, observations of damage to the lungs and heart organs macroscopically (color, diameter, and weight) and microscopically (count of necrotic cells with a magnification of 400x in 5 fields of view). Then the three data are added up and calculate the average. The average results were analyzed by parametric statistics using software SPSS version 16.0. For measurement of hb levels, macroscopic observations (diameter and weight), and microscopic examination of the lungs and heart used the test, one way ANOVA while for macroscopic observations (color) of the lungs and heart test was , the kruskal-walis used with a significance value <0.05.

**RESULTS AND DISCUSSION:**

The preparation of lung and heart organs was stained using HE (hematoxylin) which was then observed with a binocular microscope in 5 fields of view with 400x magnification. The results of the observation of *scoring* histopathological changes in the lungs and heart are as follows:

Pembuatan preparat organ paru dan jantung dilakukan pewarnaan menggunakan HE (hematoksilin) yang kemudian diamati dengan mikroskop binokuler dalam 5 lapang pandang perbesaran 400x. Adapun hasil pengamatan *skoring* perubahan histopatologi pada organ paru dan jantung sebagai berikut:

Table 2. Degree of Lung Histopathological Damage

Treat ment	Degree of Lung Damage (n)				Rating result	Avera ge
	Nor mal	Ligh t	Med ium	We ight		
P0	3	3	-	-	9	1,5
P1	1	3	2	-	12	2
P2	-	3	2	1	13	2,167
P3	-	1	3	2	16	2,667

Table 3. Degree of Cardiac Histopathological Damage

Treat ment	Degree of Heart Damage (n)				Rating result	Avera ge
	Nor mal	Ligh t	Med ium	We ight		
P0	3	3	+	+	3	0,5
P1	+	3	3	+	9	1,5
P2	+	4	2	+	8	1,3
P3	+	2	4	+	10	1,67

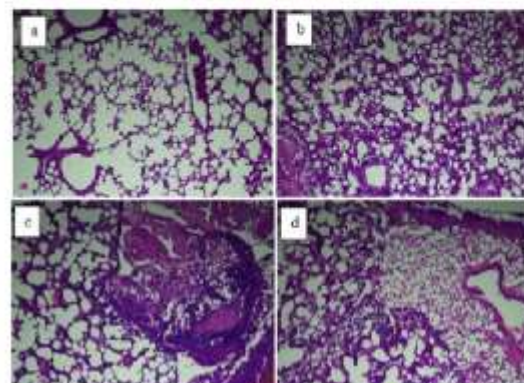


Figure 1: Lungs of mice that are not exposed and exposed to mosquito coil smoke.

Notes: (a) Mice's lungs were not exposed to mosquito coil smoke, (b) Mice's lungs were exposed to insect repellent smoke for 4 hours, (c) Mice's lungs were exposed to mosquito coil smoke for 6 hours, (d) Mice's lungs were exposed to medicinal smoke mosquito burn for 8 hours

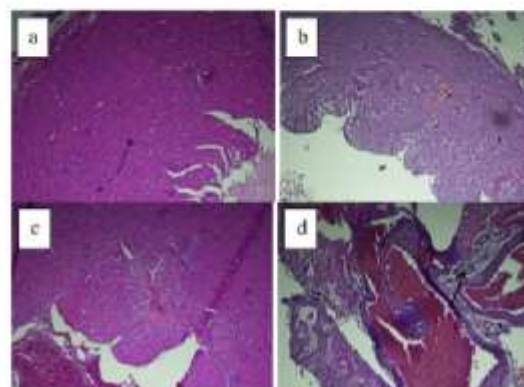


Figure 2. Unexposed mice heart and exposed to mosquito coil smoke.

Notes: (a) Mice's heart that is not exposed to mosquito coil smoke, (b) Mice's heart is exposed to mosquito coil smoke for 4 hours, (c) Mice's heart is exposed to mosquito coil smoke for 6 hours, (d) Mice's heart is exposed to medicinal smoke mosquito for 8 hours.

According to table 2, the degree *score* of lung damage increased in each treatment. The mean value of P0, P1, P2, and P3 shows 1.5; 2; 2,167; and 2,667. Thus, in Figure 1 you can see the changes in cells from each treatment. This differs from the degree of damage to the heart. Based on table 3, the average value of P0, P1, P2, and P3 shows 0.5; 1.5; 1.3; and 1.67 which means that there is a decrease in P2 and an increase again in P3, which is also seen in Figure 2.

The results of statistical tests of the degree of lung damage using *Kruskal-wallis* showed a significant difference between the treatment and the degree of lung damage with a *p-value* of 0.015. While the statistical results of the *Kruskal-Wallis* test of the degree of heart damage showed that there was no significant difference between the treatment and the degree of heart damage.

Table 4. Average levels of hemoglobin in mice

Treatment	Hemoglobin level (g/dl)
P0	14.6
P1	17.4
P2	15
P3	17.4

For hemoglobin levels in table 4, there was also a change in each treatment. The average value of P0, P1, P2, and P3 is 14.61; 17.4; 15.05; and 17.4, thus, there is an increase in P1 then decreases in P2, and increases again at P3. The results of the *one-way ANOVA* statistical test showed differences in hemoglobin levels in the treatment with a *p-value* of 0.000 and in the *post hoc* test, it showed a significant difference in each treatment.

#### DISCUSSION:

Observation of lungs' microscopic organ performed on each treatment to see how many pycnotic core, then determine the degree of damage to lung cells divided into four categories: normal, minor damage, moderate damage, and severe damage. The degree of lung damage showed an increase in each treatment. According to Figure 1, P0 (control) it is visible that the lung cells in a normal state, then P1 began experiencing mild degrees of damage although there are still normal cells. Next, P2 started to suffer moderate damage where the core pycnotic has more. While in P3, lung cells have started to experience severe damage, there are pycnotic nuclei 25-50% of the entire field of view. As explained by<sup>4</sup> that lungs are organs that often experience pathological abnormalities. Exposure to particles that are concentrated in the air in the short term can induce lung inflammation in mice. Harmful particles or free radicals that enter the respiratory tract can cause acute or chronic effects. The acute effects of free radicals on the respiratory system can directly damage the epithelial cells of the airways, especially the alveoli epithelium or stimulate the occurrence of inflammatory processes and damage to lung tissue. The damaged cells experienced degeneration in microscopic changes, such as the cells become crowded, cytoplasmic swelling, cell membranes flake with widespread surface, and mitochondrial<sup>5</sup>. Degeneration itself is an abnormal change in the morphology of tissues or cells. Some lesions referred to as degeneration show temporary or adaptive changes in function.<sup>6</sup> Therefore, in this study it was shown that the longer the exposure time, the more severe the degree of

lung damage will be.

Microscopic observations of the heart organs also occur as well as observations of the lungs, by determining the number of pycnotic cells to determine the degree of damage to the heart organ. At P0, cardiomyocyte cells appear normal and do not find their pycnotic cell, while the treatment group as P1, P2, and P3 the visible pycnotic appear in normal and cell with the level of cardiac cell damage was found. This is in line with research conducted by<sup>7</sup> which stated that *Rattus norvegicus* mice exposed to e-cigarette smoke for 30 days were shown to have a mild effect of cell death on heart muscle. Based on Table 3, it shows the average value of each treatment increased despite a decrease in P2, but P3 experienced highest increase. This happens because more COHb (Carboxyhemoglobin) circulates in the lungs and lead to the bloodstream and continue to the heart through the left atrium and ventricle. Then the CO (carbon monoxide) in circulation was caused throughout the cardiac cells that deprived of oxygen, which can cause cell death in the form of a core that is experiencing pycnotic or can be referred as the core pycnotic.<sup>1</sup> In conclusion, this study shows that the longer the exposure time, the more damage to cells in the heart, although not statistically significant.

In the observation of hemoglobin P0 levels, it is known that the hemoglobin level is low because the average value obtained is 14.61 g/dl. Thus it is not in accordance with the normal value of Hb in male mice, which is 15.90g/dL.<sup>8</sup> However, in the treatment group such as P1, P2, and P3 now appears the increasing that exceeds normal value. Such as P1 and P3 have elevated levels of hemoglobin than P2. It does not correspond to a study conducted by<sup>9</sup> which states that exposure to mosquito coils for 6 hours resulted in a decrease in hemoglobin as erythrocytes cell will be lysed and release hemoglobin, followed by hemoglobin level decreasing in the blood. However, the increase in hemoglobin levels in this study was in accordance with research conducted by<sup>10</sup> which stated that the average hemoglobin level in the control group was smaller than the treatment group, due to peroxidation events in the membranes inside the erythrocytes. The more smoke of mosquito coils that enters the body, the higher the oxygen consumption due to depict rapid consumption of oxygen (*respiratory burst*) as well as the formation of large amounts of *reactive oxygen species* (ROS), which can make a chain reaction to form peroxides fat<sup>11,12,13,14,15,16,17,18,19,20</sup>. Thus, in this study, there was a statistically significant difference between the length of exposure time and hemoglobin levels in mice.

## CONCLUSION:

In conclusion, the four treatment groups that were carried out in this research, there were differences in the value of the Hb levels of mice. Histopathological observation of the heart of mice showed that there was a difference in the control group with the treatment which indicated the presence of pyknotic cells in damaged heart cells. The variation of time has effect on the histopathological condition of the heart of mice and the higher the treatment, the higher the degree of damage to heart cells. Microscopically, lung cell tissue was damaged when exposed to mosquito coil smoke, it is the presence of pyknotic nuclei in P2 an P3 treatments. The variation in the length of time exposure to mosquito repellent smoke on mice, for 0 hours (control), 4 hours, 6 hours, and 8 hours turned out to have an effect on the histopathological conditions of the lungs of mice, the longer the exposure time, the higher the level of damage.

## ACKNOWLEDGEMENT:

This work was supported by the STIKES RS Anwar Medika.

## CONFLICT OF INTEREST:

The authors declare no conflict of interest.

## REFERENCES:

- Dahniar A. Pengaruh Asap Obat Nyamuk Terhadap Kesehatan Dan Struktur Histologi Sistem Pernafasan. *J Kedokt Syiah Kuala*. 2011;11(1):52-59.
- Oktavia L, Oktavia L. Faktor-Faktor Yang Berhubungan Dengan Kepatuhan Ibu Kecamatan Baturaja Timur Kabupaten Oku Jurnal Kesehatan Abdurahman Palembang Vol . 9 No . 2 . September 2020 Lisa Oktavia 142 Jurnal Kesehatan Abdurahman Palembang Vol . 9 No . 2 . September 2020. *J Kesnat Abdurahman Palembang*. 2020;9(2):41-48.
- Rinalty EDD, Soekanto A, Sahadewa S, Jus Buah Naga Sebagai Antioksidan pada Tikus Putih (*Rattus norvegicus*) yang Dipapar Obat Anti Nyamuk Bakar Terhadap Perubahan Histopatologi Sel Nephron. *J Ilm Pendidik Eksakta*. 2017;11(September):235-249.
- Hayu TP, Soekanto A. Pengaruh Pemaparan Uap Anti Nyamuk Elektrik yang Mengandung Allathrin terhadap Berat dan Warna Patau-Patau Tikusi. *J Ilm Kedokt Wijaya Kusuma*. 2018;5(1):26. doi:10.30742/jikw.v5i1.3
- Rondang Tambun, Harry P. Limbong, Christika Pinem, Ester Manurung. Pengaruh Ukuran Partikel, Waktu Dan Suhu Pada Ekstraksi Fenol Dari Lengkuas Merah. *J Tek Kim USU*. 2017;5(4):53-56. doi:10.32734/jtk.v5i4.1555
- Morissette MC, Shen P, Thayapuran D, Stämpfli MR. Impacts of peroxisome proliferator-activated receptor- $\gamma$  activation on cigarette smoke-induced exacerbated response to bacteria. *Eur Respir J*. 2015;45(1):191-200. doi:10.1183/09031936.00004314
- Kusuma AE, Oktania D. Pengaruh Pemberian Thymoquinone Terhadap Gambaran Histopatologi Jantung Tikus Putih (*Rattus norvegicus*) Galur Sprague dawley Yang Diinduksi Asap Rokok The Effect Of Thymoquinone On Cardiac Histopathological Appearance Of Sprague dawley Strain White Rat . 2019;8:84-89.
- Akin-Osanaiye, Nok a J, Amlabu E, Haruna E. Assessment of Changed in Serum Haematological Parameters in the Assessment of Changed in Serum Haematological Parameters in the Plasmodium berghei Infected Albino Mice Treated with Neem (*Azadirachta indica*) Extracts. *Int J Chem Biol Sci*. 2015;1(3): 148(September):148-152.
- Niswah C, Syarifah S, Sany F. Pengaruh ASAP Anti Nyamuk Kertas Bakar Terhadap Jumlahleukosit PADA MENCIT (*Mus musculus* L.). *J SaintHealth*. 2018;2(1):40. doi:10.51804/jh.v2i1.17740-45
- Prihati DR, Nugrahani I. Pengaruh Papanan Obat Nyamuk Terhadap Kadar Hemoglobin Tikas Betina Usia Pubertas. *J Terpadu Ilmu Kesnat*. 2015;4(2):90-93.
- Ansori ANM. A mini-review of the medicinal properties of Okra (*Abelmoschus esculentus* L.) and potential benefit against SARS-CoV-2. *Indian J Forensic Med Toxicol*. 2021; 15(1): 852. DOI: 10.37506/ijfort.v15i1.13523.
- Husen SA, Setyawan MF, Syadzha MF, Susilo RJK, Hayaza S, Ansori ANM, Alamsjah MA, Ilmi ZN, Walandari PAC, Padjastuti P, Awang P, Winarni D. A Novel Therapeutic effects of *Sargassum ilicifolium* Alginate and Okra (*Abelmoschus esculentus*) Pods extracts on Open wound healing process in Diabetic Mice. *Research J. Pharm. and Tech* 2020; 13(6): 2764-2770. doi: 10.5958/0974-360X.2020.00491.6.
- Ansori ANM, Fadholly A, Proboningrat A, Hayaza S, Susilo RJK, Naw SW, Posa GAV, Yuseizal YP, Sibeno MT, Suppto TH, Soegijanto S. In vitro antiviral activity of *Pinus merkusii* (Pinaceae) stem bark and cone against dengue virus type-2 (DENV-2). *Res J Pharm Technol*. 2021; 14(7):3705-8. doi: 10.52711/0974-360X.2021.00641.
- Husen SA, Ansori ANM, Hayaza S, Susilo RJK, Zamidah AA, Winarni D, Pamapuyuk H, Darmanto W. Therapeutic Effect of Okra (*Abelmoschus esculentus* Moench) Pods Extract on Streptozotocin-Induced Type-2 Diabetic Mice. *Res J Pharm Technol*. 2019; 12(8):3703-3708. doi: 10.5958/0974-360X.2019.00633.4
- Ansori ANM, Kharisma VD, Solikhah TI. Medicinal properties of *Muntingia calabura* L.: A Review. *Res J Pharm Technol*. 2021; 14(8):4509-2. doi: 10.52711/0974-360X.2021.00784.
- Ansori ANM, Fadholly A, Hayaza S, Susilo RJK, Inayattillah B, Winarni D, Husen SA. A Review on Medicinal Properties of *Mangosteen* (*Garcinia mangostana* L.). *Res J Pharm Technol*. 2020; 13(2):974-982. doi: 10.5958/0974-360X.2020.00182.1
- Ansori ANM, Kharisma VD, Fadholly A, Tacharina MR, Antonius Y, Parikesit AA. Severe acute respiratory syndrome coronavirus-2 emergence and its treatment with alternative medicines: A review. *Res J Pharm Tech*. 2021; 14(10).
- Fadholly A, Ansori ANM, Kharisma VD, Rahmahani J, Tacharina MR. Immunoinformatics of Rabies Virus in Various Countries of Asia: Glycoprotein Gene. *Res J Pharm Technol*. 2021; 14(2): 883-886. doi: 10.5958/0974-360X.2021.00157.8.
- Proboningrat A, Kharisma VD, Ansori ANM, Rahmawati R, Fadholly A, Posa GAV, Sudjarwo SA, Rantam FA, Achmad AB. In silico Study of Natural inhibitors for Human papillomavirus-18 E6 protein. *Res J Pharm Technol*. 2022; 15(3):1251-6. doi: 10.52711/0974-360X.2022.00209
- Kharisma VD, Aghuta A, Ansori ANM, Widyananda MH, Rizky WC, Dings TGA, Derkho M, Lysakova I, Antonius Y, Rosadi I, Zainul R. Herbal combination from *Moringa oleifera* Lam. and *Curcuma longa* L. as SARS-CoV-2 antiviral via dual inhibitor pathway: A viroinformatics approach. *J Pharm Pharmacogn Res*. 2022; 10(1): 138-146.

# Duration Exposure effect of Anti Mosquito Coils smoke on Lung and Microscopic condition of Heart and Haemoglobin in Mice

## ORIGINALITY REPORT

<b>7</b> SIMILARITY INDEX	<b>17%</b> INTERNET SOURCES	<b>13%</b> PUBLICATIONS	<b>30%</b> STUDENT PAPERS
------------------------------	--------------------------------	----------------------------	------------------------------

## PRIMARY SOURCES

<b>1</b>	<b>Submitted to Poltekkes Kemenkes Banjarmasin</b> Student Paper	<b>2%</b>
<b>2</b>	<b>www.rjptonline.org</b> Internet Source	<b>2%</b>
<b>3</b>	<b>Submitted to Syiah Kuala University</b> Student Paper	<b>2%</b>
<b>4</b>	<b>f1000research.com</b> Internet Source	<b>1%</b>
<b>5</b>	<b>repository.ubaya.ac.id</b> Internet Source	<b>&lt;1%</b>
<b>6</b>	<b>balimedicaljournal.org</b> Internet Source	<b>&lt;1%</b>
<b>7</b>	<b>www.frontiersin.org</b> Internet Source	<b>&lt;1%</b>

Exclude quotes Off  
Exclude bibliography Off

Exclude matches Off